

Blokády hrudnej steny

Jakub Hlásny

II. KAIM SZU FN_sP FDR BB

CEEA Košice 2019

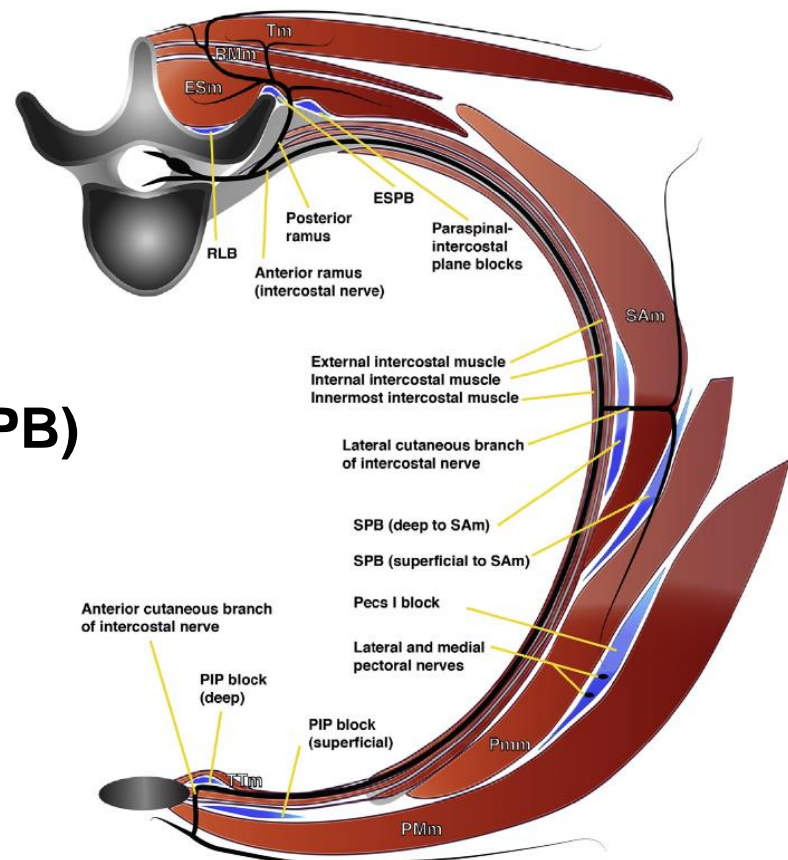


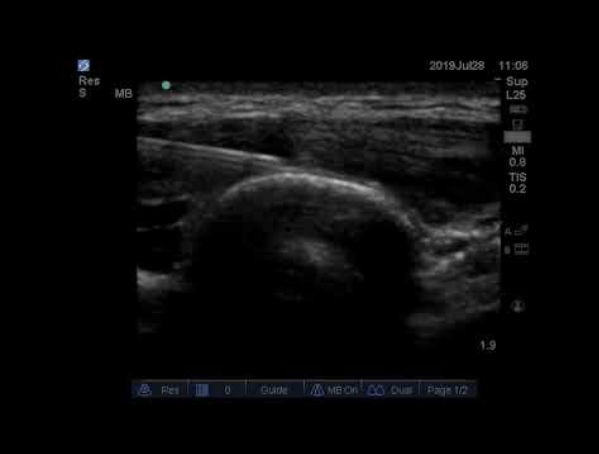Prehlásenie

Nemám konflikt záujmov

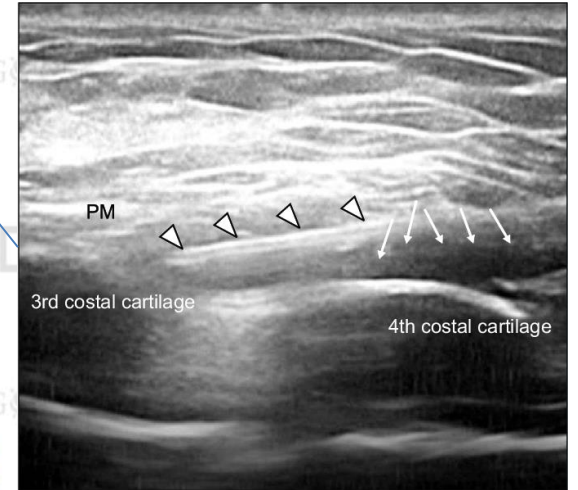
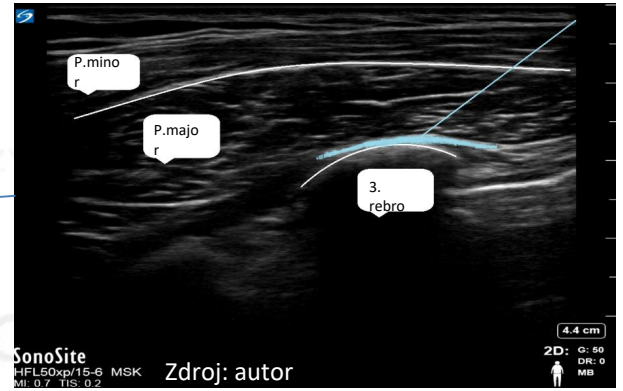
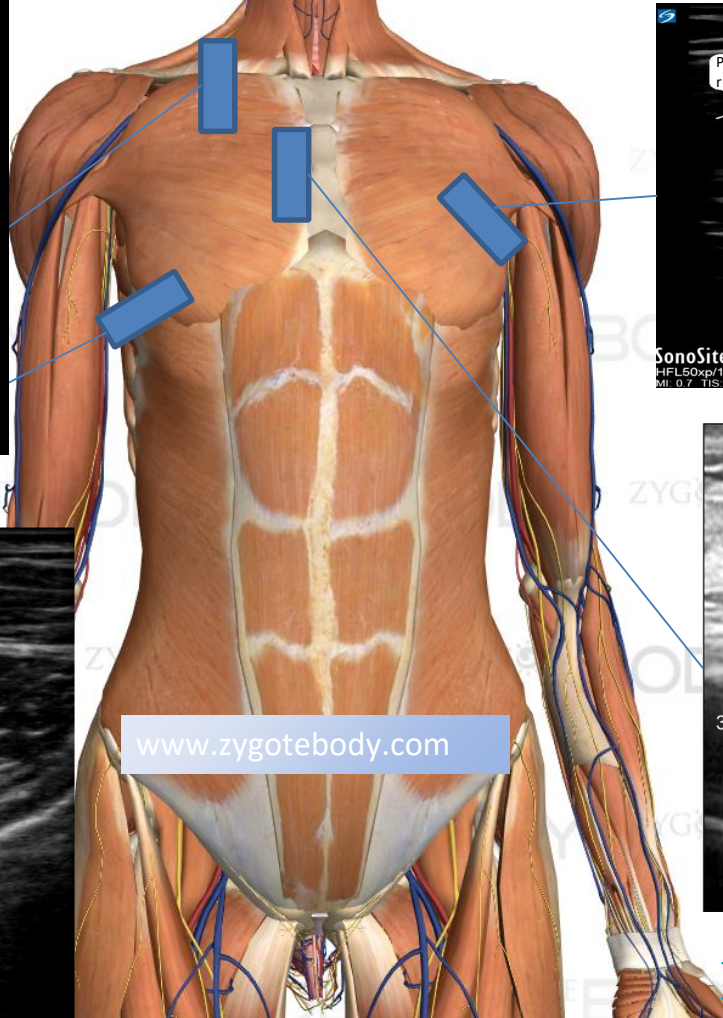
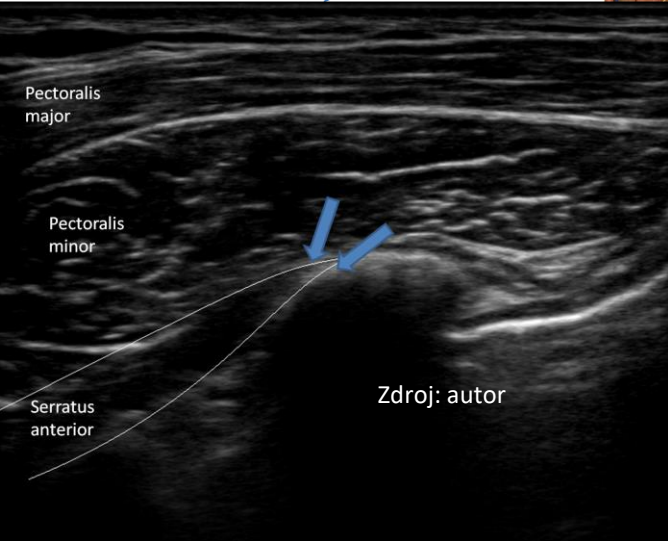
Možnosti blokád hrudníka

1. Epidurální Anestézia (EDA)
2. Retrolaminar block
3. **Paravertebrální blok (PVB)**
4. **Erektor spinae blok (ESP)**
5. Intercostální blok
6. Intrapleurální blok
7. **Serratus anterior plane block (SAPB)**
8. **PECS bloky**
9. Clavipectoral fascia plane block
10. Pecto intercostal fascia plane block
11. Povrchový krční plexus





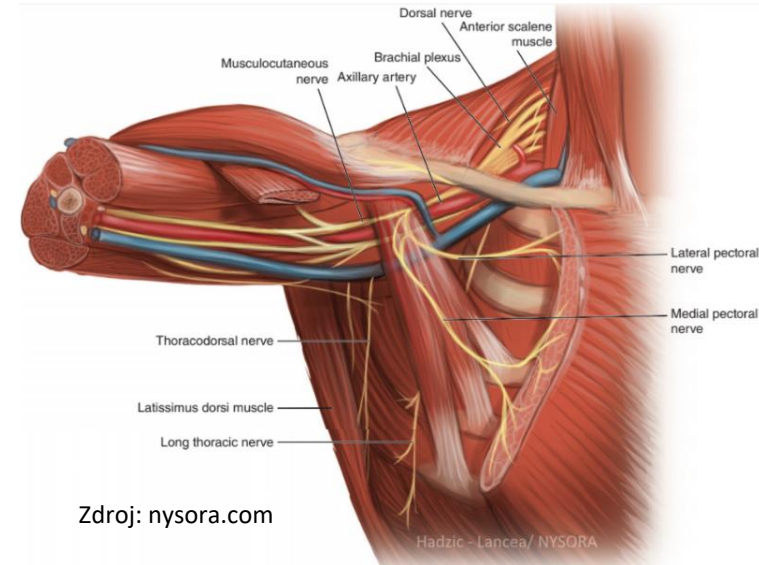
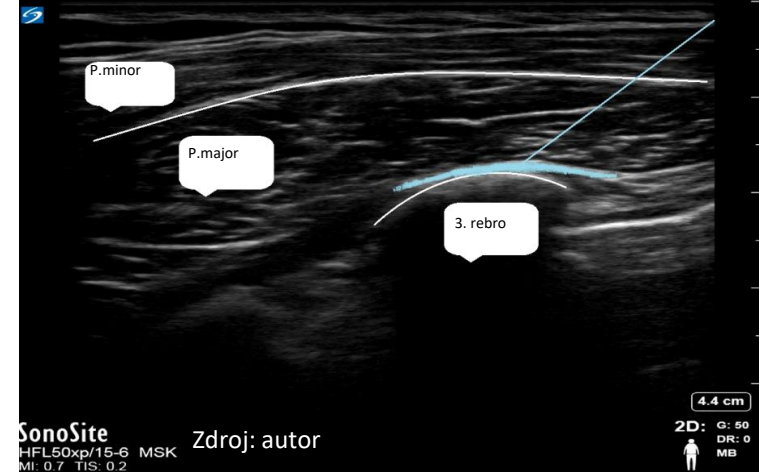
<https://www.youtube.com/watch?v=JvgJwsBXT0Y>



https://www.researchgate.net/figure/Ultrasound-image-of-pecto-intercostal-fascial-plane-block-Pectoralis-major-PM-3rd-and-fig2_315763971

PECS bloky

- Prof. Blanco 2013
- intermediate blok trupu
- Riziko: pneumotorax, krvácanie
- Blok anestezuje prednú hrudnú stenu
- Publikované boli: randomizované kontrolované štúdie
- Indikácia – operácie hrudnej steny (prsníky), axila
- KI – koag. parametre, sepsa, alerggia na LA, (absolútna) nesúhlas pacienta
- Dávkovanie: 10-20ml bupivacain 0,25% (na stranu)
- Odporúčaný IMMA



Základné blokády

Techniky, ktoré majú nízke riziko komplikácií a sú nenáročné. Lekár veľmi rýchlo získava kompetenciu a bezpečnosť pacienta je vysoká.

- PECS bloky
- Serratus anterior plane blok (SAPB)
- Erektor spinae plane blok (ESP)

Stredne obtiažne bloky

Techniky so stredným rizikom komplikácií lekár získava dostatočné kompetencie až po dostatočne dlhej praxi.

- Interkostálny blok
- Rhomboid intercostal subserratus plane block (RISS)
- Mid point transverse process to pleura (MTP)

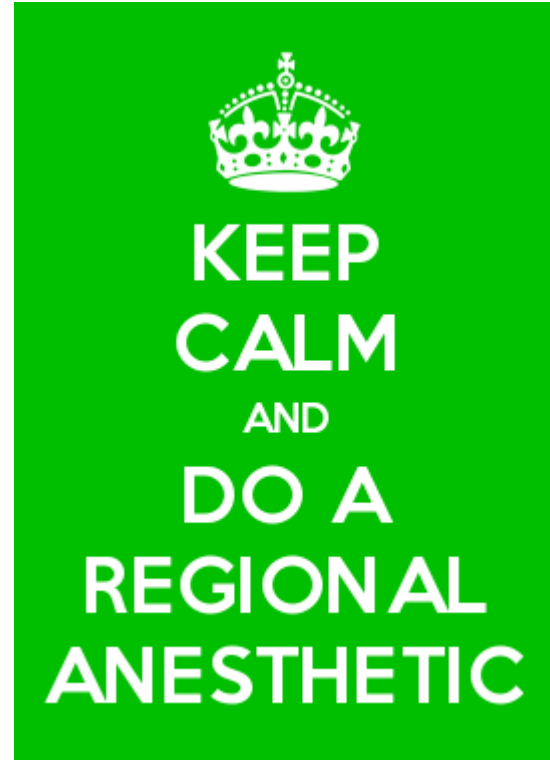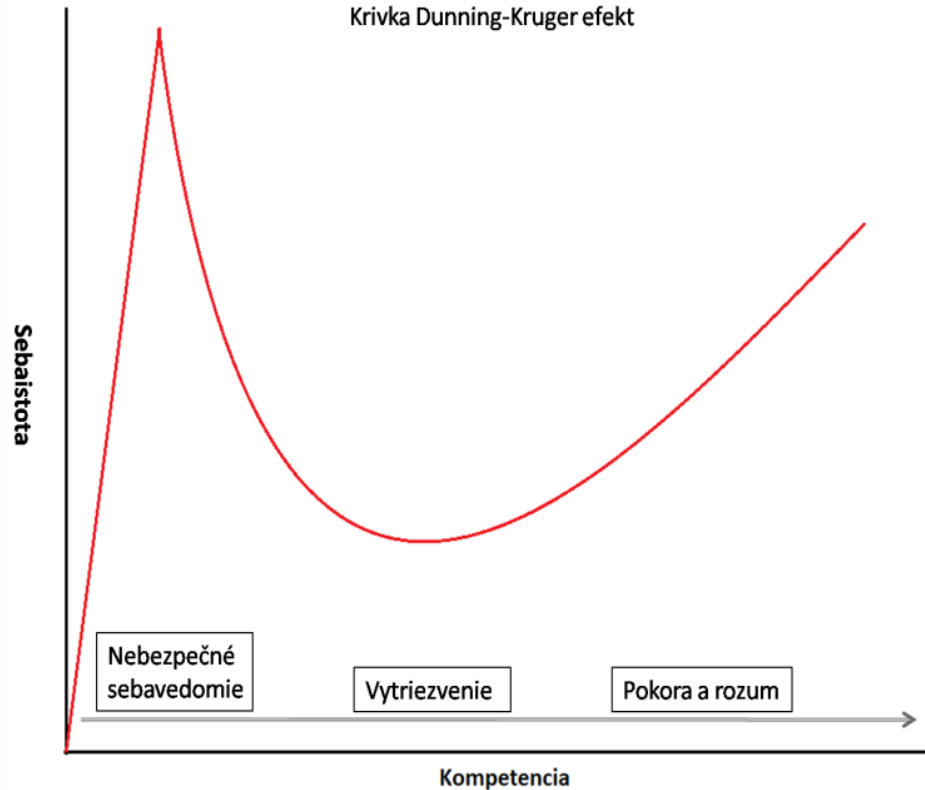
Obtiažne bloky

Blokády s vysokým potenciálnym rizikom poškodenia pacienta. Lekár získava dostatočné skúsenosti až po intenzívnom tréningu RA. Väčšinou ide o lekárov so zvýšeným záujmom o túto oblasť v odbore AIM.

- Kontinuálne periférne bloky (akékoľvek)
- Paravertebrálny blok (PVB)
- Hrudný epidurálny blok
- **Clavipectoral fascia plane blok***

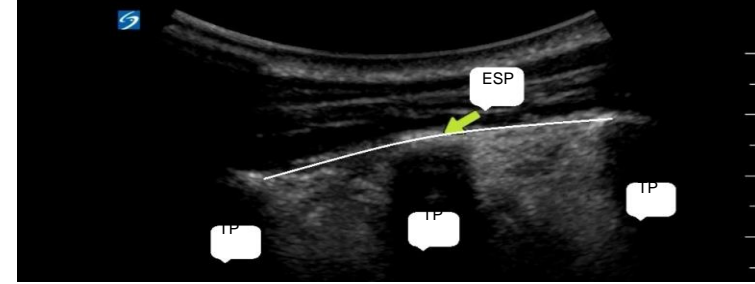
* **blokáda je zaradená medzi náročné pre nedostatok klinických dát, je potrebný ďalší výskum v tejto oblasti.**

Dunning-Krugerova krivka



Erektor spinae blok

- Ferero a kol. 2016 (algeziológia)
- „Basic“ blok trupu

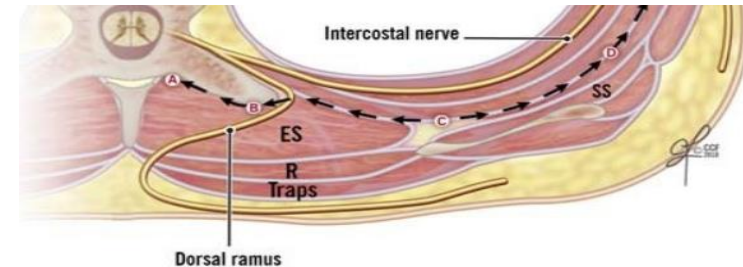


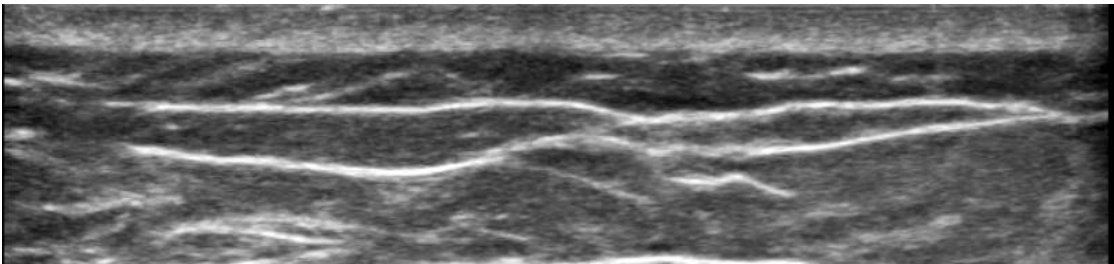
REGIONAL ANESTHESIA AND ACUTE PAIN

DARING DISCOURSE

Interfascial Plane Blocks *Back to Basics*

*Hesham Elsharkawy, MD, MBA, MSc, * Amit Pawa, MBBS(Hons), FRCA, †† and Edward R. Mariano, MD, MAS§*





ESPB pre sériovú fraktúru rebier

Curb Your Enthusiasm: Erector Spinae Plane Block —‘Because It Is Easy’ Is Not a Good Reason to Do It!

November 2019 Issue



Vishal Uppal, MBBS, FRCA, EDRA

Assistant Professor and Director of Regional Anesthesia Fellowship Program;
Department of Anesthesia, Pain Management and Perioperative Medicine,
Dalhousie University
Co-author



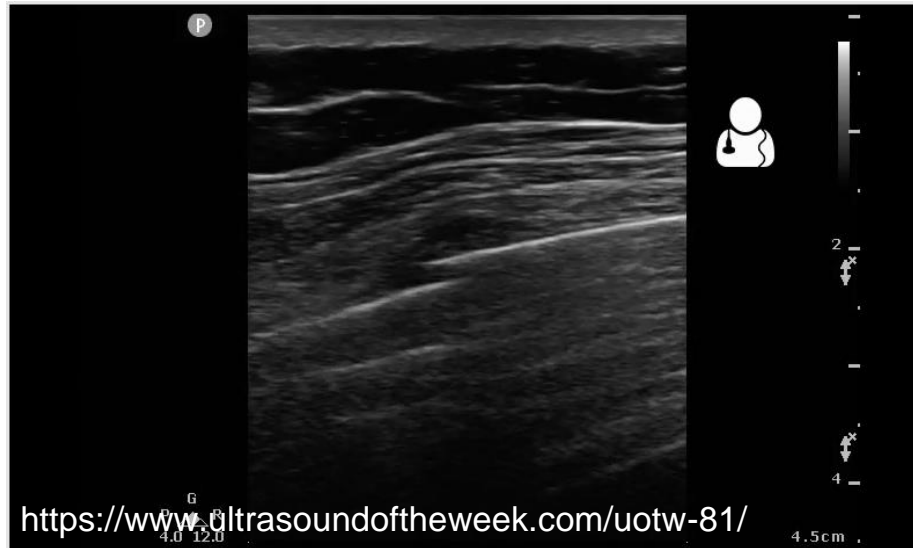
Vivian H Y Ip, MBChB, MRCP, FRCA

Clinical Associate Professor, University of Alberta Hospital
Co-author



ESP a zlomeniny rebier

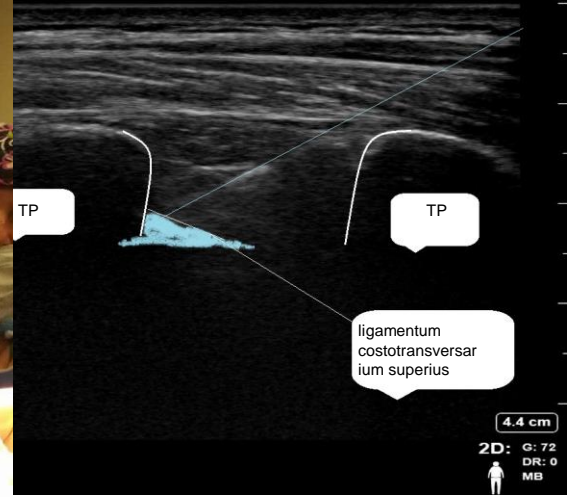
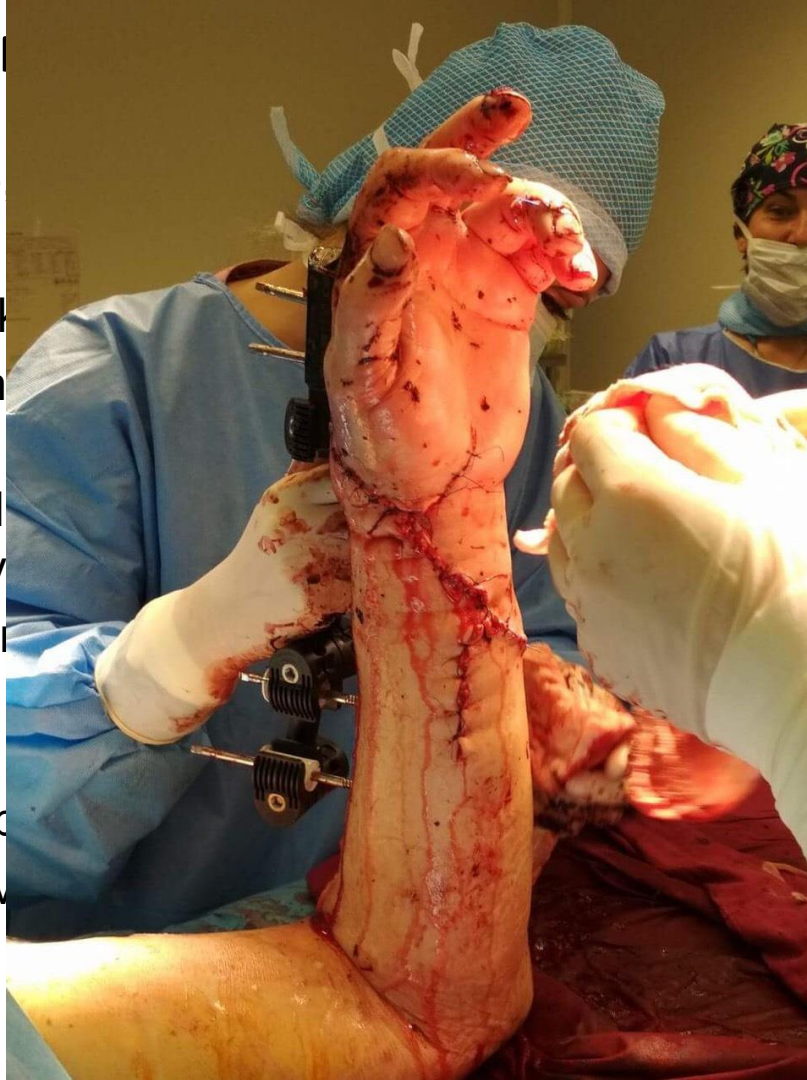
- Senzitivita USG pri zlomeninách rebier je **98,3%**¹.
- Senzitivita RTG pri zlomeninách rebier je 40,7%¹.



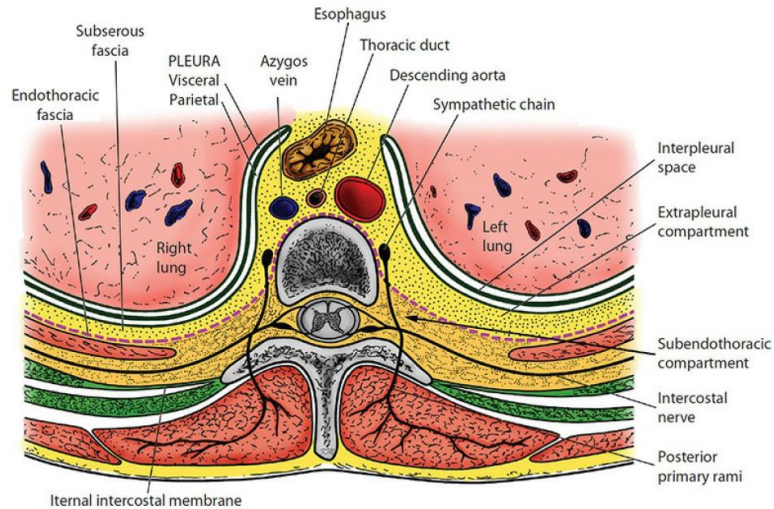
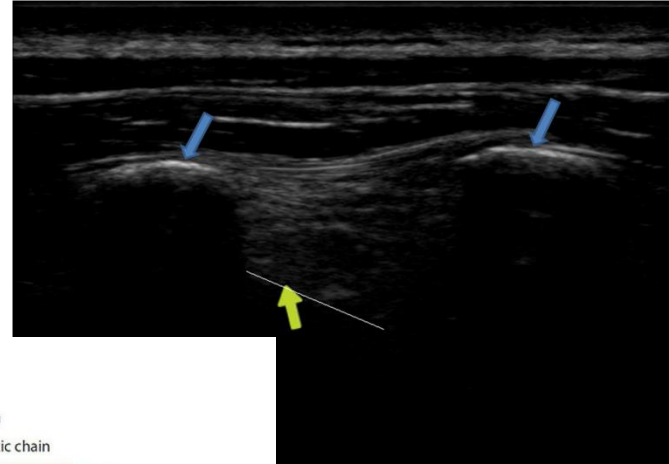
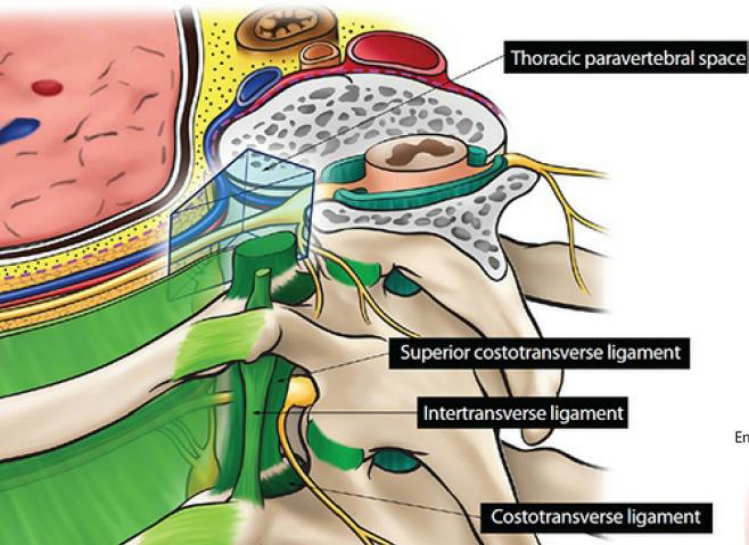
¹M. Yousefifard, Comparison of Ultrasonography and Radiography in Detection of Thoracic Bone Fractures; a Systematic Review and Meta-Analysis, In: Emergency, 2016

<https://www.ncbi.nlm.nih.gov/pmc/articles/PMC4893752/>


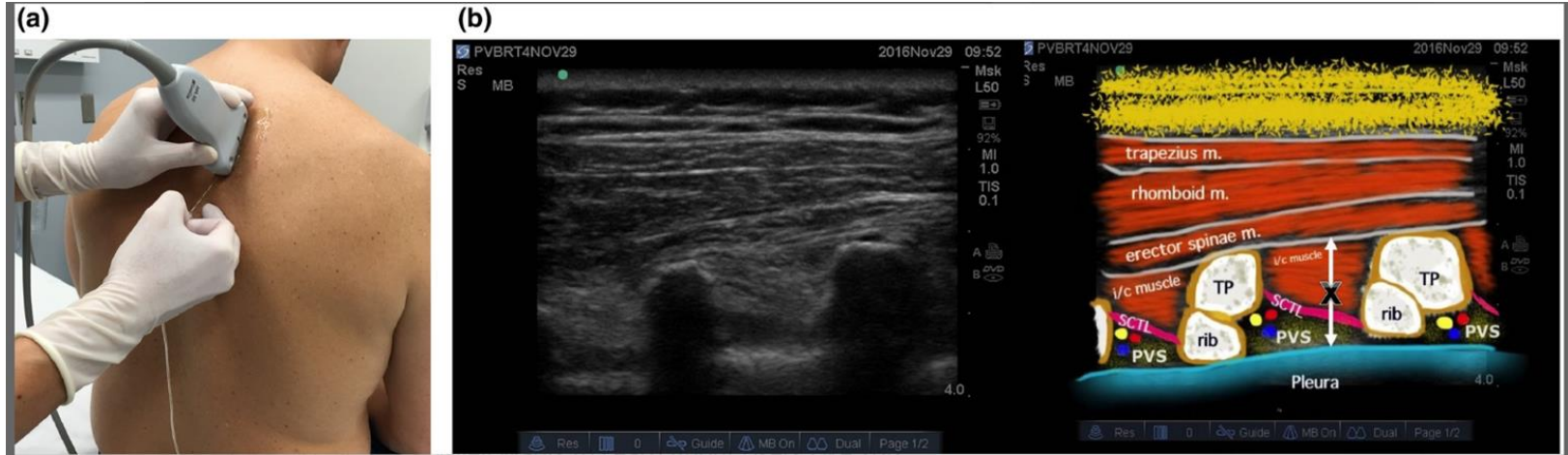
- Popisovaný už v 1905
- „Advanced“ blok trupu
- Riziko: pneumotorax, k
- Blok anestezuje hrudn
- gangliá
- Publikované boli: rand
- štúdie, zlepšuje prežív
- Indikácia – operácie h
- nefrektómia....
- KI – koag. parametre,
- (absolútna) nesúhlas p
- Dávkovanie: 5ml bupiv
- adrenalin (LAST !)



Paravertebrálna blokáda



Mid-point-transverse-process to pleura (MTP)



Costache, I., de Neumann, L., Ramnanan, C. J., Goodwin, S. L., Pawa, A., Abdallah, F. W., & McCartney, C. J. L. (2017). *The mid-point transverse process to pleura (MTP) block: a new end-point for thoracic paravertebral block*. *Anaesthesia*, 72(10), 1230–1236. doi:10.1111/anae.14004

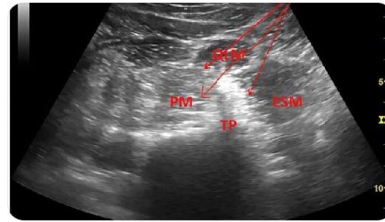
Pragi

k RA

Tweet



Hari Kalagara MD @Kalag... · 15 hod. ✓
 Chris time to make it.....Triple Combo Pack.....🌟"LPQLESP"🌟.....LP+QL+ESP. (Works for Anything)



1 4



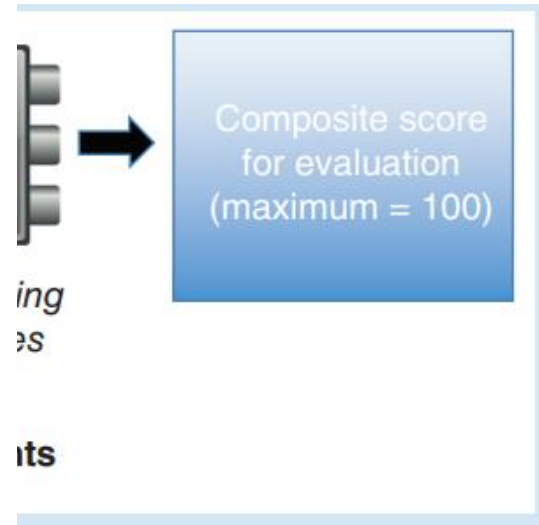
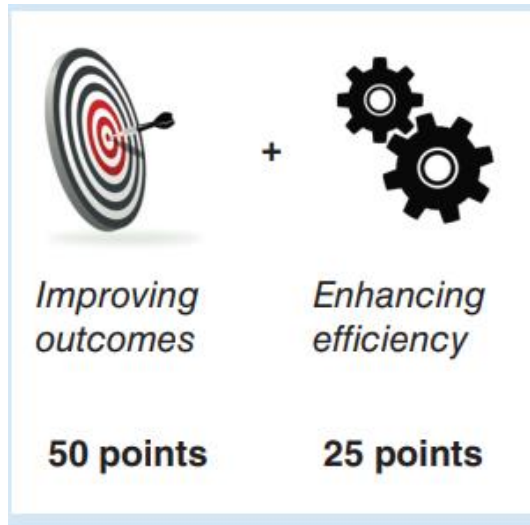
Peter Merjavy @PeterMerj... · 11 hod. ✓
 I am confused like @amit_pawa. Lumbar ESP spreads towards sacral plexus (S1) but the reference only stated "significant contrast material around L4-5 nerve, femoral and obturator nerve at L5 level". I can't see any more information about the L-ESP sacral spread

1



Peter Merjavy @PeterMerj... · 11 hod. ✓
 Anterior QLB (Transmuscular, TEQUILA) involves majority of lumbar plexus

Tweetnite svoju odpoved'



Multimodálna individualizovaná analgézia/anestézia

Optimalizácia

Pre lekára

Pre pacienta

- Pracovať na **sebe**

○

Research article | [Open Access](#) | Open Peer Review | [Published: 31 July 2019](#)

Effect of opioid-free anaesthesia on post-operative period in cardiac surgery: a retrospective matched case-control study

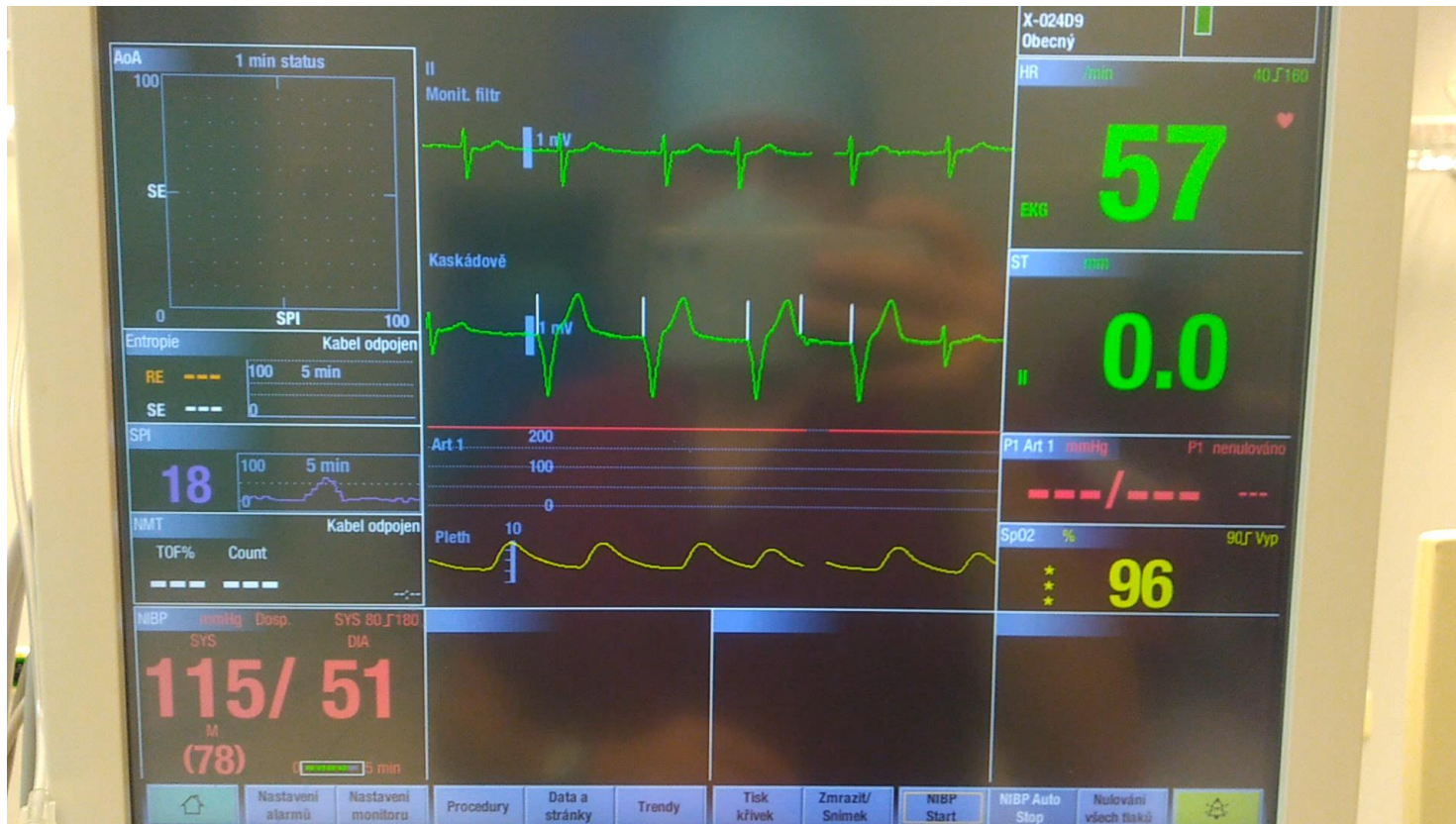[Pierre-Grégoire Guinot](#) , [Alexandra Spitz](#), [Vivien Berthoud](#), [Omar Ellouze](#), [Anis Missaoui](#), [Tiberiu Constandache](#), [Sandrine Grosjean](#), [Mohamed Radhouani](#), [Jean-Baptiste Anciaux](#), [Jean-Philippe Parthiot](#), [Jean-Pierre Merle](#), [Nicolas Nowobilski](#), [Maxime Nguyen](#) & [Belaid Bouhemad](#)

○

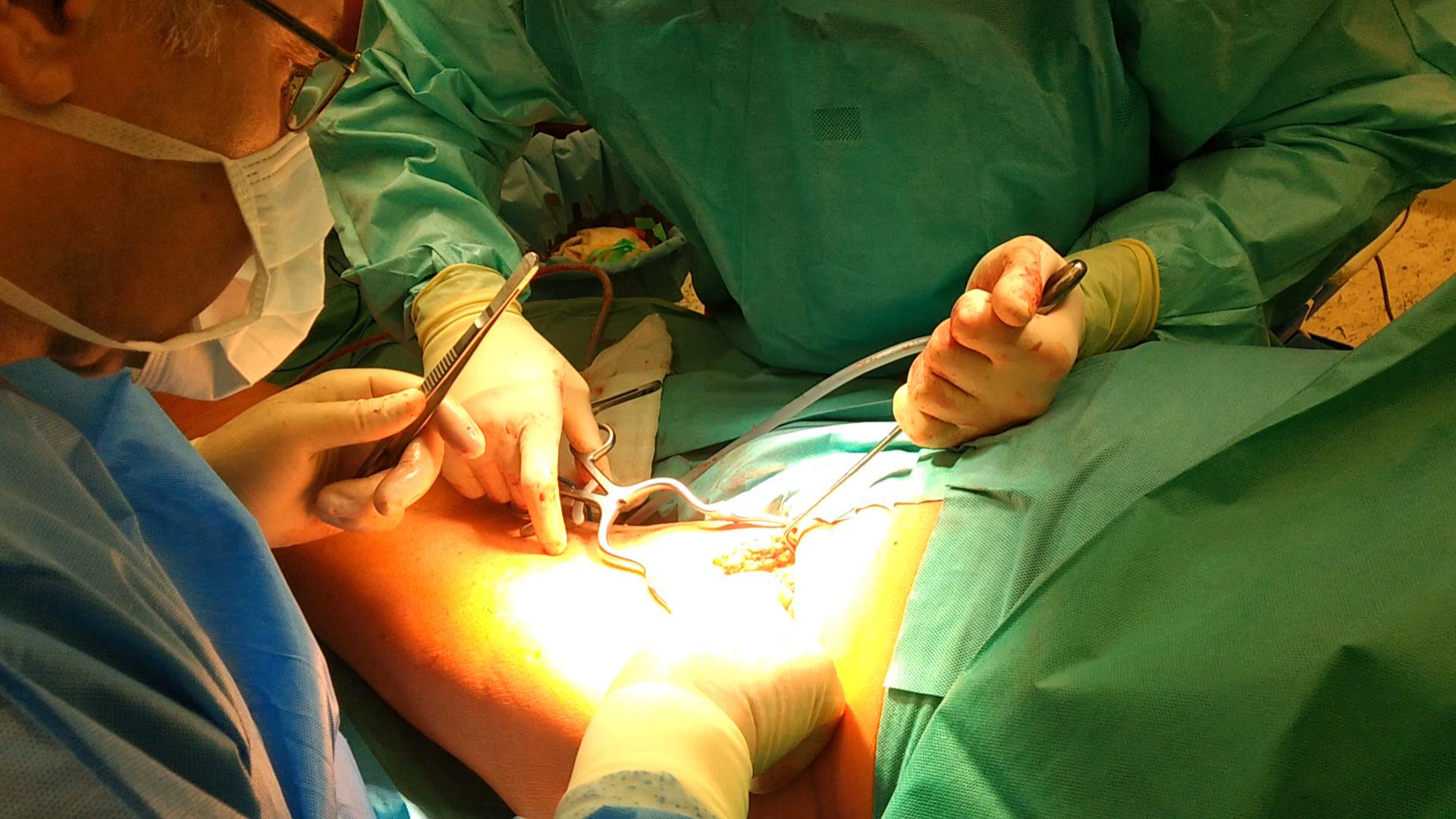
○

- Kor
- Vyu [BMC Anesthesiology](#) **19**, Article number: 136 (2019) | [Cite this article](#)
- **Ex** **1876** Accesses | **9** Altmetric | [Metrics](#)

- **Nové postupy v medicínskej praxi ??**



Awake FP bypass v PNB RA



Zdroje informácií

- **ES**

-
-
-

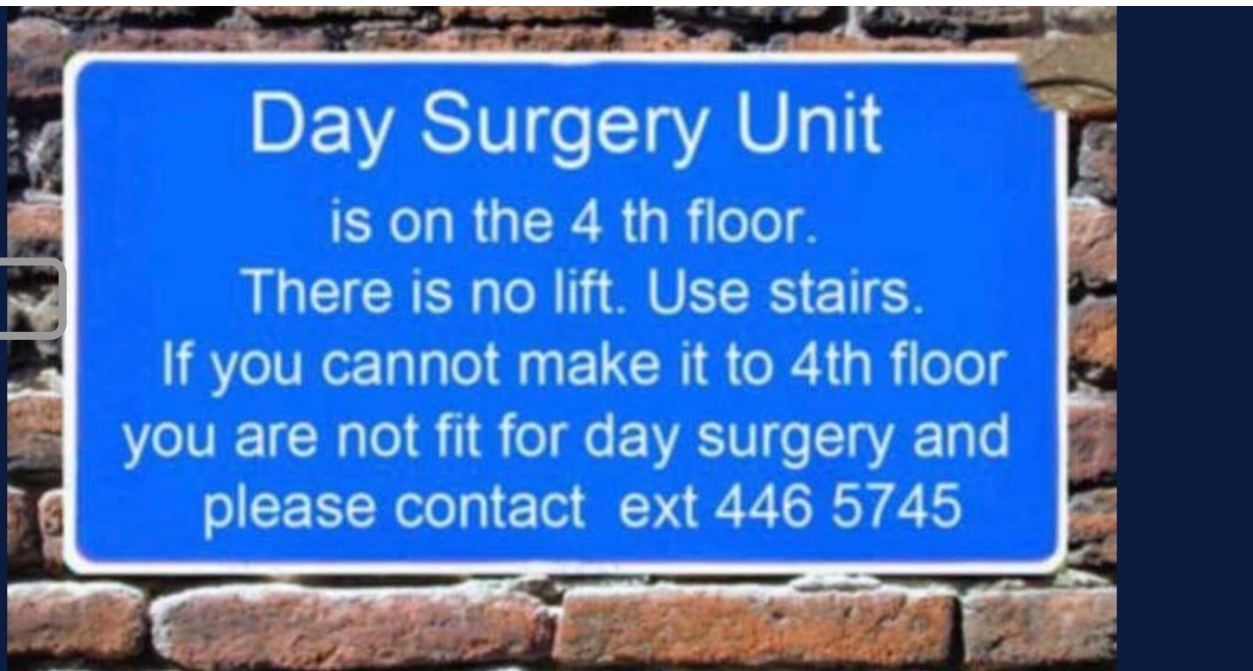- **Sci**

- **SK**

-
-
-

- **AS**

- **NY**



Ďakujem za vašu pozornosť

